Vega Medical Services

Post Traumatic Syringomyelia Arachnoiditis and Subarachnoid Space Obliteration

Nattida Kampuang, PhD, Dr. Pongsathron Liengwattanakol, MD

"This comprehensive literature review elucidates how post-traumatic arachnoiditis and fibroconnective scarring obliterate the spinal subarachnoid space, transforming traumatic leptomeningeal inflammation into progressive, hydrodynamically driven syringomyelia."

Date: 22 November 2026
Address: 3/6, The Primary 101, Ladphrao 101 Road, Klongchan, Bangkapi, Bangkok 10240 Thailand
Contact us: +66 652 258 2599
E-mail: nattida.k@vegastemcell.com

Abstract

Post-traumatic syringomyelia represents a devastating and insidious neurological condition characterized by the delayed formation of fluid-filled cavities within the spinal cord parenchyma following trauma. While mechanical disruptions of the craniocervical junction or congenital central canal variations have traditionally characterized classical primary syringomyelia, secondary post-traumatic syringomyelia arises through fundamentally distinct pathobiological mechanisms. Central to this condition is the development of chronic adhesive arachnoiditis, wherein traumatic mechanical injury combined with subarachnoid blood extravasation incites an aggressive leptomeningeal inflammatory cascade. Over months to decades, this persistent inflammatory reaction evolves into dense collagenous fibrosis, organizing into adhesive bands and arachnoid webs that mechanically tether the spinal cord and obliterate the spinal subarachnoid space. Obliteration of the subarachnoid pathways halts the physiological, bidirectional oscillation of cerebrospinal fluid, precipitating severe localized pressure gradients, altered pulse pressure transmission, and microvascular ischemia within the spinal parenchyma. Fluid is driven through enlarged perivascular spaces into watershed necrotic cores, resulting in progressive cystic coalescence and parenchymal expansion. This literature review synthesizes multi-center clinical findings, experimental animal models, and histopathological investigations to deliver a deep-dive analysis of arachnoiditis-induced subarachnoid space obliteration in syringomyelia, examining the cascade from traumatic hemato-inflammatory signaling to hydrodynamic failure and progressive myelopathy.

Keywords: Post-traumatic syringomyelia, spinal arachnoiditis, subarachnoid space obliteration, meningeal fibrosis, cerebrospinal fluid dynamics, spinal cord injury

© 2026 Vega Medical Services. All rights reserved.

Introduction

Post-traumatic syringomyelia is a devastating and disabling consequence of spinal trauma after a few months, years, or even decades after the trauma. Cavitation occurs over a range of 4-10 % and is symptomatic in the series of spinal cord injuries; however, asymptomatic cystic degeneration and collection at a late stage may occur in 28% of patients(Kleindienst, Laut, Roeckelein, Buchfelder, & Dodoo-Schittko, 2020). Post-traumatic cavitation can be considered as another acquired biomechanical and biological injury of the spinal leptomeninges versus syringomyelia (congenital anomaly, present from birth, or recreating an open embryologic central canal in patients with hindbrain malformations)(Dietz, Sheth, Castillo, Freeman, & Nauta, 2026).

As noted in our previous review, early embryological neurulation and post-natal central canal stenosis define the structural baseline of the spinal cord, establishing isolated compartments that are susceptible to abnormal fluid retention. Furthermore, as discussed in our earlier review, mechanical constriction at the craniovertebral junction in conditions such as Chiari malformation type I alters macroscopic cerebrospinal fluid oscillation, generating transmedullary pressure differentials that push fluid into the parenchyma. However, in the setting of traumatic spinal cord injury, a completely distinct pathological sequence unfolds. The initiating insult does not originate from anatomical crowding at the skull base, but from direct trauma to the spinal column and meninges, accompanied by local hemorrhage and parenchymal contusion(Dietz et al., 2026).

Trauma lesions, parenchymal cavitations, adhesions, arachnoiditis. It is a thin, trabecular, nonvascularized membrane apposed to the dura on the other side and maintaining the subarachnoid space (between it and the pial membrane) open to low pressure maintained by the pulsation of cerebrospinal fluid due to cardiac action(Abel, Howard, & Menezes, 2014; Nadeem, Baig, Tariq, & Shamim, 2022). Laceration/contusion of the membrane with extravasation of autologous blood products into the subarachnoid space leads to exuberant fibroinflammation. This acute inflammation resolves with exuberant fibroblastic proliferation and progressive collagen deposition to mature fibrotic adhesions(Abel et al., 2014).

It gradually destroys the subarachnoid space of the spine in part or in entirety. The normal course of fluid flow is entirely suspended and the channel for fluid is altered; the spinal cord is strongly attached to the covering dura and vertebral column. This literature review summarizes the current understanding of cells, mechanics, and hydrodynamics that result in arachnoid fibrosis and obliteration of the subarachnoid space, culminating in post-traumatic syringomyelia (Abel et al., 2014; Fadila et al., 2025; Xu et al., 2021).

1.Traumatic Insult and the Meningeal Inflammatory Cascade

Post-traumatic syringomyelia is caused by the acute mechanical forces of vertebral fractures, dislocations, or severe deceleration injuries. These forces disrupt the spinal parenchyma and the meninges that cover it(Choi, Brantley, & Heiss, 2026). Early subarachnoid blood products are essential for arachnoiditis development. Contusive parenchymal necrosis will result in focal tissue absences and free blood in the intrathecal compartment is a very potent chemical irritant to the arachnoid tissues(Abel et al., 2014; Tang, Davies, & Davies, 2003).

Experimental models of post-traumatic syringomyelia corroborate clinical observations that trauma alone rarely produces extensive, progressive cystic cavitation unless accompanied by subarachnoid blood or severe leptomeningeal inflammation. Conversely, mild contusion with subarachnoid blood deposition reliably results in chronically expanding cysts, whereas mild injury alone results in localized, self-limited myelomalacia without an

© 2026 Vega Medical Services. All rights reserved.

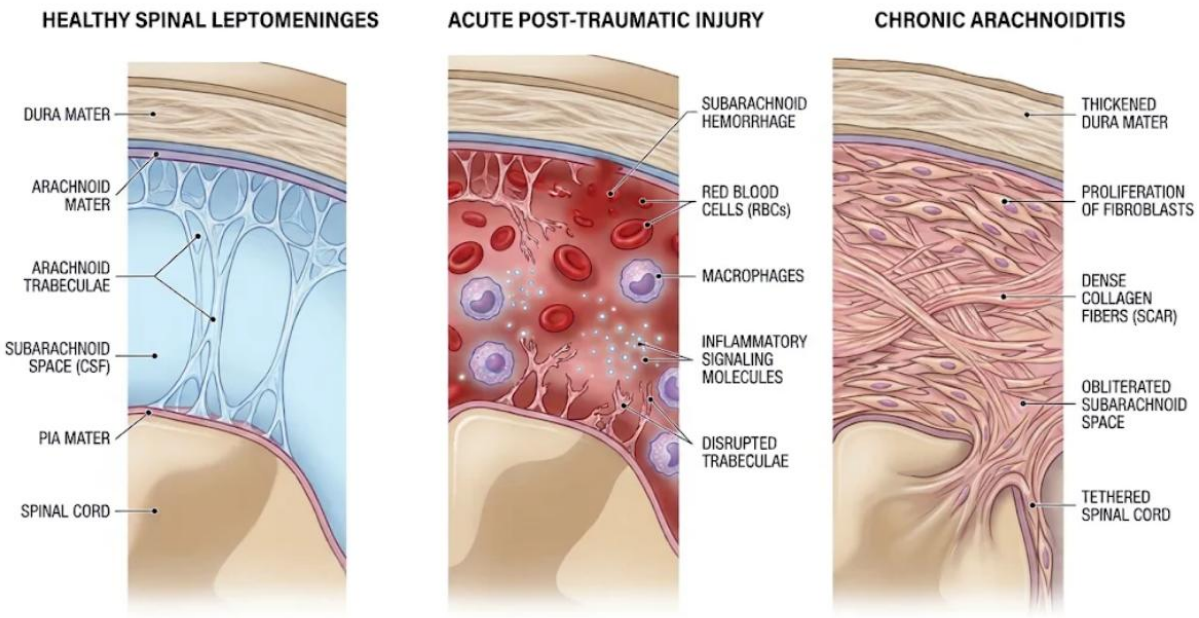

Figure 1. Pathophysiological progression of post-traumatic spinal arachnoiditis. Schematic representation (not to scale) comparing healthy spinal leptomeninges with an open CSF-filled subarachnoid space (left), acute post-traumatic subarachnoid hemorrhage with disrupted trabeculae, RBC extravasation, macrophage infiltration, and inflammatory signaling (middle), and chronic arachnoiditis marked by dural thickening, fibroblast proliferation, dense collagen scarring, subarachnoid space obliteration, and spinal cord tethering (right).

expanding syrinx. Hemorrhage and hemolysis of eccentrically extravasated red blood cells conspire to expose the subarachnoidal environment to toxic hemoglobin, reactive heme degradation products, and free iron. Nonneural inflammatory cells, such as hematogenous macrophages and microglia, quickly invade leptomeninges and perivascular spaces and clear cellular debris and iron pigments(Xu et al., 2021).

During the early inflammatory phase, there is a high local release of pro-inflammatory cytokines, growth factors, and chemokines. Inflammatory signals then recruit quiescent arachnoid cap cells, perivascular pericytes, and adventitial fibroblasts to injury. In the confined volume of the subarachnoid space, the response becomes chronic rather than subsiding quietly(Abel et al., 2014; Nadeem et al., 2022). Activated fibroblasts/inflammatory cells codeposit fibronectin, laminin, and fibrillar collagen in abundance on the thin arachnoid trabeculae. This chronic active inflammation progresses into a dense fibrocollagenous scar phase (largely inactive) that can persist for months to years(Nadeem et al., 2022).

As shown in the **figure 1** describing the cellular cascade of post-traumatic arachnoiditis, mechanical parenchymal contusion and subarachnoid hemorrhage trigger macrophage activation, massive pro-inflammatory cytokine release, and fibroblastic recruitment, which rapidly transforms the delicate arachnoid trabeculae into dense, collagenous fibroconnective sheets.

2.Fibroconnective Scarring and Subarachnoid Space Obliteration

The histopathologic evolution of arachnoiditis results in disruption of intrathecal anatomy. The normal subarachnoid space (fluid space) is one where CSF can flow bidirectionally and where the spinal cord can be cushioned. And during

© 2026 Vega Medical Services. All rights reserved.

fibrogenesis of leptomeninges, the lace-like portions of arachnoid trabeculae are substituted with thick, opaque sheets and bands of dense fibrous tissue(Caplan, Norohna, & Amico, 1990; Xu et al., 2021).

These fibrotic bands predominate in the subarachnoid space and confer dense adhesiveness to the visceral pial covering of the surface of the spinal cord, arachnoid membrane, and parietal dura mater. The sectioned spinal cords of posttrauma syringomyelic patients from autopsy similarly reveal obliterated subarachnoid space adjacent to the site of spinal cord injury such that the cord itself is incorporated into dural and bony adhesions and tethered to them. This so-called tethering of the spinal cord leads to continuous mechanical (radial and longitudinal) tension on cord parenchyma(Squier & Lehr, 1994; Xu et al., 2021).

Furthermore, arachnoid fibrosis exhibits distinct morphological patterns depending on the severity of the initial insult. In focal arachnoiditis, the scarring is confined to less than three spinal segments, presenting as discrete dorsal arachnoid webs, fibrous curtains, or localized intradural cysts(Martinelli & Massimi, 2026). Conversely, in extensive arachnoiditis, which involves four or more contiguous spinal cord segments, the fibroconnective matrix forms circumferential cuffs that completely encircle the spinal cord. This extensive, multilevel scarring compartmentalizes the spinal subarachnoid space into isolated, non-communicating pockets of cerebrospinal fluid(Choi et al., 2026).

As shown in the **figure 2** illustrating structural obliteration of the subarachnoid space, the circumferential accumulation of dense collagenous scar tissue bridges the pia, arachnoid, and dura mater, firmly tethering the spinal cord and obliterating the functional cerebrospinal fluid pathways around the circumference of the cord.

This is one of the reasons why such a slow obliteration of the vascular system of the spinal cord occurs. The anterior and posterior spinal arteries and their feeding branches (radicular feeders and punctate pial branches) run in the leptomeninges. These are encased by dense collagen deposition and fibrotic contraction with intimal hyperplasia, thickening of the adventitia, and narrowing of the lumen of the vessels(Caplan et al., 1990). The obliteration of such vessels results in chronic ischemia of the tissue, and notably, of the gray matter of the cord and the watershed areas between the anterior and posterior supply of spinal arterial vessels. The spinal cord is therefore tethered, ischemic, and deprived of its fluid protective cushion(Nadeem et al., 2022).

3.Hydrodynamic Disruption and Extracanalicular Syrinx Genesis

The physical mismatch in the subarachnoid space is a breach of the biophysical laws of homeostasis of the spinal cord fluid. In normal subjects, the column of cerebrospinal fluid absorbs and dissipates the kinetic energy of exertional activities (cardiac systole, respiration, etc.). In cardiac systole, the arterial blood floods the intracranial compartment and the cerebrospinal fluid immediately is forced to the compliant subarachnoid space which acts as a buffer of the pressure pulse wave of the cardiac systole(Abel et al., 2014; Fadila et al., 2025).

Fluid cannot be dammed between this arachnoid scar filling the subarachnoid space segment where it invades and partially or completely replaces the spinal subarachnoid space. The cerebrospinal fluid pressure pulse wave, propagating caudally from the cranial vault, finds a high-resistance physical barrier at the upper edge of the arachnoid scar(Klekamp, 2013). Since the obliterated subarachnoid spaces are non-communicating, the systolic pressure pulse energy is dissipated into the compliant tissue of the spinal cord. The sudden arrest of flow results in an enormous pressure differential across the block with high pulse pressure above the block and low pressure below the block (Fadila et al., 2025; Kim, Oh, Kim, & Park, 2014).

This local hydrodynamic blockade, here driving fluid into the cord substance,

© 2026 Vega Medical Services. All rights reserved.

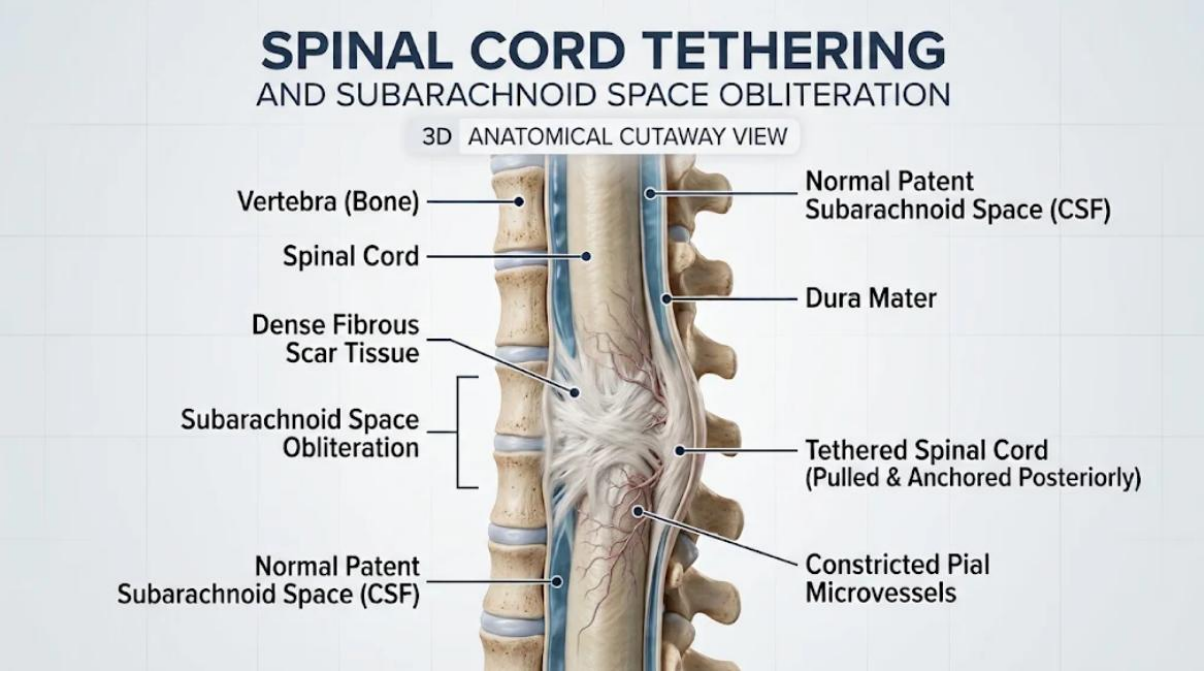

Figure 2. Focal subarachnoid space obliteration and posterior spinal cord tethering. 3D anatomical cutaway view showing dense fibrous scar tissue obstructing the subarachnoid space, anchoring the spinal cord posteriorly to the dura mater, and constricting pial microvessels, while normal patent cerebrospinal fluid (CSF) channels persist above and below the lesion.

is applied by two complementary physical principles. The first is therefore the Bernoulli effect: established lateral hydrostatic pressure of cerebrospinal fluid reduced to about half at the ostial openings to the subarachnoid or adjacent edges of scars, resulting in a greatly increased speed of cerebrospinal fluid flowing around these structures. This results in a Venturi suction effect over the surface of the spinal cord because of the local pressure drop. Simultaneously, the elevated pulse pressure above the obstruction generates a continuous transmedullary pressure gradient that pulls fluid radially inward from the subarachnoid space into the spinal parenchyma(Fadila et al., 2025; Martinelli & Massimi, 2026).

As shown in the **figure 3** detailing the hydrodynamic mechanisms of fluid entry, systolic pulse waves redirected against the subarachnoid obstruction generate severe transmedullary pressure gradients, driving cerebrospinal fluid through dilated Virchow-Robin perivascular spaces directly into ischemic parenchymal tissue.

This influx of fluid is directed by the perivascular channel system (Virchow-Robin spaces). In normal conditions, these perivascular sheath spaces are filled with interstitial fluid and are the resorption area of interstitial fluid. Yet the pathological systolic pressure gradient drives fluid flow back from the perivascular spaces into spinal cord parenchyma. The extreme dilatation of perivascular spaces in the perisyringeal parenchyma at the site of post-traumatic arachnoid scarring is demonstrated histologically and experimentally(Choi et al., 2026; Martinelli & Massimi, 2026).

The spinal cord fluids are already affected. Neuropathological studies tend to associate post-traumatic syringomyelia with eccentric cores of necrotic tissue (myelomalacia) within dorsal and central gray matter and not with the ependymal central canal(Squier & Lehr, 1994). The site of development differs from that of primary congenital syringomyelia. Continued influx of fluid surpasses the fluid storage capacity in the spinal parenchyma combined with

© 2026 Vega Medical Services. All rights reserved.

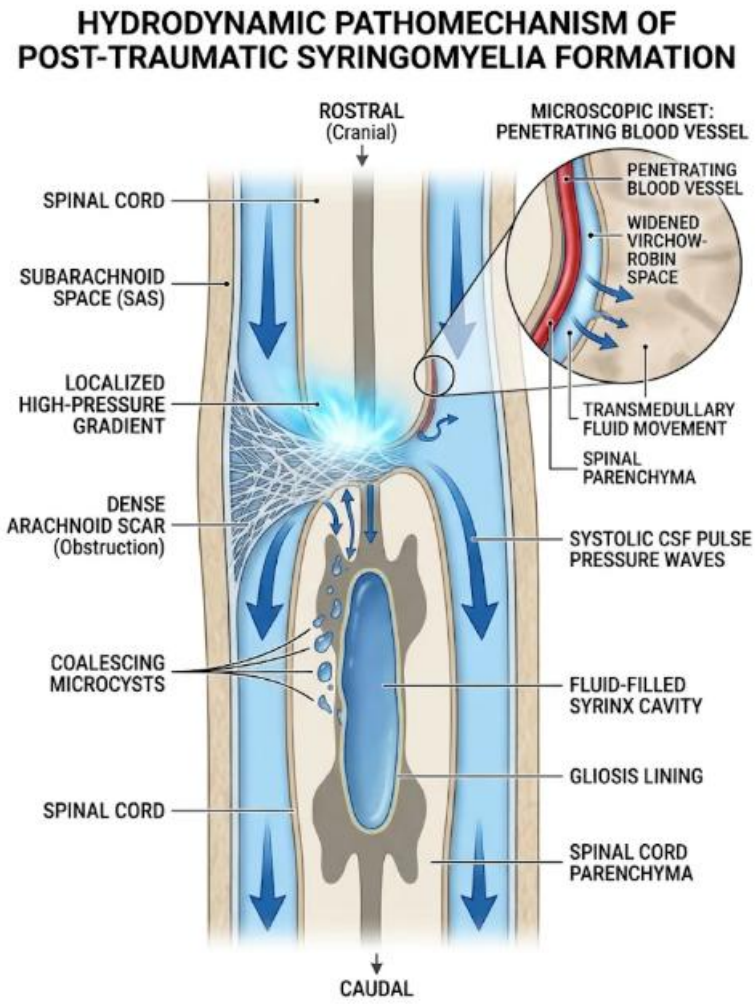

Figure 3. Hydrodynamic mechanism of post-traumatic syringomyelia. Obstruction of the subarachnoid space (SAS) by an arachnoid scar traps systolic cerebrospinal fluid (CSF) pulse waves, creating a localized high-pressure gradient. This drives transmedullary fluid entry through widened Virchow-Robin spaces (inset), resulting in microcyst coalescence and a gliosis-lined syrinx cavity.

residual traumatic tissue necrosis and latent ischemia due to strangulation of meningeal vessels. Intermittent edema coalesces into microcysts coalescing into a large, expansive, longitudinal syrinx cavity with dense fibrillary reactive gliosis(Xu et al., 2021).

Within these forces, the formed syrinx is subjected to hydrodynamic forces. During episodes when thoracic and abdominal pressures change rapidly, such as sneezing, coughing, or Valsalva maneuvers when the dural sac is compressed, this epidural venous plexus becomes engorged rapidly, and 'sloshing' forces within the cavity of the syrinx are propagated dynamically. Propulsive pressure waves drive fluid droplets rostrally and caudally into areas of normal spinal cord above and below the injured spinal region, thus progressively lengthening the syrinx(Dietz et al., 2026; Kim et al., 2014; Kleindienst et al., 2020).

Discussion

Post-traumatic syringomyelia associated with arachnoiditis presents complex diagnostic and therapeutic challenges. The clinical hallmark of this condition is a delayed, progressive neurological deterioration following an initial period of post-injury functional stability. The

© 2026 Vega Medical Services. All rights reserved.

interval between the primary trauma and the clinical manifestation of syringomyelia is notoriously variable, ranging from several months to more than four decades, with an average latency often exceeding five to twenty years(Choi et al., 2026; Dietz et al., 2026; Kleindienst et al., 2020).

Clinically, patients will frequently manifest new or progressive neurologic signs over those already present at the original level of spinal cord injury. Radicular neuropathic pain is also the first and most common symptom and is often worsened by coughing, sneezing, or exercise. This is in association with the sensory deficits, classically dissociated sensory loss of pain/temperature by disruption of spinothalamic fibers in cross-section but preservation of light touch/proprioceptive awareness attributed to peripheral dorsal columns(Dietz et al., 2026; Kim et al., 2014). Radial syrinx expansion into the anterior and lateral horns leads to lower motor neuron weakness and muscle atrophy, spasticity, and progressive autonomic or sphincter dysfunction. In the most severe cases, with maximal rostral extension, there may be syringobulbia with dysphagia, vocal cord paralysis, facial numbness, and nystagmus with rupture into the cervical segments and medulla oblongata(Dietz et al., 2026; Fadila et al., 2025; Kleindienst et al., 2020).

Magnetic resonance imaging remains the radiological examination of choice to assess the accompanying arachnoid pathologies and for diagnostic work-up in post-traumatic syringomyelia. The multilobulated intramedullary fluid cavity, which appears hyperintense, is readily visualized using high-resolution T2 sequences(Xu et al., 2021). However, thin arachnoid webs, discrete septations, and focal adhesive bands frequently are not seen on standard structural imaging. Thus, more specialized techniques must be employed like constructive interferences in the steady state (CISS), fast imaging employing steady-state acquisition (FIESTA), or phase-contrast cine-MRI Cine-MRI enables the quantitative real-time measurement of CSF flow velocity and turbulence and may also demonstrate focal blocks and turbulent jets at the borders of obliterated subarachnoid spaces(Martinelli & Massimi, 2026).

The management of post-traumatic syringomyelia is controversial, and treatment is dictated primarily by the degree of arachnoiditis evident and the clinical course of the patient. Patients with incidental or minimally symptomatic cavities and stable clinical status are typically treated conservatively using analgesia, neuromodulation, physiotherapy, and frequent radiological follow-up. Interestingly, some patients will have spontaneous collapse/regression of their syrinx (presumably spontaneously fenestrating the syrinx wall into the surrounding subarachnoid space/cerebrospinal fluid). Surgery is warranted, however, in the case that neurological deficits are progressive(Choi et al., 2026; Dier, Sidani, Abrams, & Furtado Freitas, 2026; Kleindienst et al., 2020).

Surgical management can be broadly divided into reconstructive operation or diversion of fluid. Reconstructive surgery treats the underlying disease: untethering of the cord and restoration of subarachnoid space patency. In the case of limited/focal arachnoiditis (i.e., <3 spinal segments) this approach (laminectomy, wide microsurgical arachnolysis, expansile duraplasty) can yield excellent results. Lysis of stiff adhesions and expansile duraplasty eliminate transmedullary pressure gradients, thereby promoting syrinx decompression and collapse(Martinelli & Massimi, 2026; Xu et al., 2021).

However, open arachnolysis is very unusual in patients with multi-level arachnoiditis (≥4 segments). The dissection of a dense, circumferential scar at multiple vertebral levels carries the risk of direct cord injury and hemorrhage. Conversely, blood will extravasate into the reactive subarachnoid space and further violate it during the operation, causing even more rapid recurrent fibrosis and re-tethering(Choi et al., 2026; Nadeem et al., 2022). In these

© 2026 Vega Medical Services. All rights reserved.

recalcitrant cases, diversion of fluid with shunts (syringosubarachnoid, syringoperitoneal, or subarachnoid-subarachnoid bypass) is required. Shunts rapidly decompress the syrinx but have a high long-term failure rate (30-50%) due to catheter occlusion, distal scarring, dislodgement, and mechanical obstruction. Surgical intervention for extensive adhesive arachnoiditis generally stabilizes symptoms rather than restoring function; surgeons currently favor individualized surgical strategies alongside the development of anti-fibrotic and neuro-regenerative therapies(Kim et al., 2014; Martinelli & Massimi, 2026).

Conclusion

Post-traumatic syringomyelia is an acquired, hydrodynamically driven disorder that exemplifies the profound consequences of disrupted leptomeningeal biology. Initiated by mechanical trauma and exacerbated by subarachnoid hemorrhage, the condition progresses through a persistent inflammatory cascade into mature, dense fibroconnective scarring. This adhesive arachnoiditis obliterates the spinal subarachnoid space, firmly tethers the spinal cord, compromises local microvascular perfusion, and halts normal cerebrospinal fluid pulse wave dissipation.

This produces transmedullary pressure gradients and Venturi suction forces, sweeping fluid retrograde via dilated perivascular channels into the vulnerable ischemic gray matter and permits expansile extracanalicular cysts to grow by propagation of a longitudinal force vector with dynamic slosh mechanics. Adequate management of disease requires a full appreciation of the extent of subarachnoid obliteration. Local lesions may be carefully untethered and duraplastied, but the extensive multilevel disease is still a challenging clinical problem to treat so as not to find reformation of fibrosis. Flow imaging, novel molecular antifibrotics, and neural regeneration will require long-term evaluation to address continuing challenges of this difficult neurosurgical condition.

© 2026 Vega Medical Services. All rights reserved.

References

Abel, T. J., Howard, M. A., 3rd, & Menezes, A. (2014). Syringomyelia and spinal arachnoiditis resulting from aneurysmal subarachnoid hemorrhage: Report of two cases and review of the literature. *J Craniovertebr Junction Spine, 5*(1), 47-51. doi:10.4103/0974-8237.135227

Caplan, L. R., Norohna, A. B., & Amico, L. L. (1990). Syringomyelia and arachnoiditis. *J Neurol Neurosurg Psychiatry, 53*(2), 106-113. doi:10.1136/jnnp.53.2.106

Choi, J. Y., Brantley, C., & Heiss, J. D. (2026). The Challenge of Treating Syringomyelia Associated with Extensive Arachnoiditis. *J Clin Med, 15*(19). doi:10.3390/jcm15197477

Dier, C., Sidani, C., Abrams, K. J., & Furtado Freitas, L. (2026). Spontaneous regression of post-traumatic syringomyelia: longitudinal mr imaging demonstrating a dynamic disease course. *Spinal Cord Series and Cases, 12*(1), 32. doi:10.1038/s41394-026-00758-w

Dietz, N., Sheth, A., Castillo, C., Freeman, D., & Nauta, H. (2026). Posttraumatic syrinx resulting in syringomyelia and syringobulbia: illustrative case. *J Neurosurg Case Lessons, 11*(11). doi:10.3171/case25797

Fadila, M., Sarrabia, G., Shapira, S., Yaacobi, E., Baruch, Y., Engel, I., & Ohana, N. (2025). Orthopedic Manifestations of Syringomyelia: A Comprehensive Review. *Journal of Clinical Medicine, 14*(9), 3145. Retrieved from doi:10.3390/jcm14093145

Kim, H. G., Oh, H. S., Kim, T. W., & Park, K. H. (2014). Clinical Features of Post-Traumatic Syringomyelia. *Korean J Neurotrauma, 10*(2), 66-69. doi:10.13004/kjnt.2014.10.2.66

Kleindienst, A., Laut, F. M., Roeckelein, V., Buchfelder, M., & Dodoo-Schittko, F. (2020). Treatment of posttraumatic syringomyelia: evidence from a systematic review. *Acta Neurochir (Wien), 162*(10), 2541-2556. doi:10.1007/s00701-020-04529-w

Klekamp, J. (2013). Treatment of syringomyelia related to nontraumatic arachnoid pathologies of the spinal canal. *Neurosurgery, 72*(3), 376-389; discussion 389. doi:10.1227/NEU.0b013e31827fcc8f

Martinelli, R., & Massimi, L. (2026). Idiopathic Syringomyelia: A Systematic Scoping Review. *Journal of Clinical Medicine, 15*(16), 6216. Retrieved from doi:10.3390/jcm15166216

Nadeem, S. F., Baig, A. N., Tariq, Q. U. A., & Shamim, M. S. (2022). Spinal arachnoiditis and syringomyelia: Review of literature with emphasis on postinfectious inflammation and treatment. *Surg Neurol Int, 13*, 299. doi:10.25259/sni_383_2022

Squier, M. V., & Lehr, R. P. (1994). Post-traumatic syringomyelia. *J Neurol Neurosurg Psychiatry, 57*(9), 1095-1098. doi:10.1136/jnnp.57.9.1095

Tang, X., Davies, J. E., & Davies, S. J. (2003). Changes in distribution, cell associations, and protein expression levels of NG2, neurocan, phosphacan, brevican, versican V2, and tenascin-C during acute to chronic maturation of spinal cord scar tissue. *J Neurosci Res, 71*(3), 427-444. doi:10.1002/jnr.10523

Xu, N., Xu, T., Mirasol, R., Holmberg, L., Vincent, P. H., Li, X., . . . Sundström, E. (2021). Transplantation of Human Neural Precursor Cells Reverses Syrinx Growth in a Rat Model of Post-Traumatic Syringomyelia. *Neurotherapeutics, 18*(2), 1257-1272. doi:10.1007/s13311-020-00987-3

© 2026 Vega Medical Services. All rights reserved.